

dogs, as is the case in humans.<sup>1,11</sup>

D-dP/dt has been demonstrated to be clinically useful in human patients with chronic MR even when it is severe.<sup>1,3,4,9</sup> In our study, MR was severe in Dogs 4 and 5 and in Dog 6. Our study suggests that D-dP/dt is also clinically useful in canine patients without regard to the severity of MR.

In a previous study evaluating canine cardiac systolic function using M-mode echocardiography, FS and EF were normal or slightly decreased in dogs with chronic and severe congestive heart failure.<sup>12</sup> In spite of the presence of myocardial failure, these indices were thought to be little changed because of the increase in preload and the decrease in afterload in the LV, attributable to MR. Myocardial contractility is, however, known to decrease in the long term with volume overload in the LV.<sup>13</sup> In addition, remarkable cardiac systolic dysfunction is detected in dogs with DCM.<sup>14</sup> In our study, severe cases of MR (Dogs 4, 5, and 6) showed the low peak dP/dt before the administration of dobutamine and propranolol in comparison with mild cases of MR (Dogs 1, 2, and 3). Cardiac systolic dysfunction may be detected with greater sensitivity at an earlier stage of canine congestive heart failure or DCM using continuous-wave Doppler echocardiography, because the isovolumetric contractile phase index (peak dP/dt) is less influenced by preload and afterload of LV in comparison with the ejectional contractile phase indices (FS and EF). Prospectively, D-dP/dt may be a useful indicator of the need for administration of positive inotropic agents, or surgical mitral valve repair in canine heart disease.

In conclusion, this study demonstrated that noninvasive estimation of peak dP/dt using transthoracic continuous-wave Doppler echocardiography was feasible in dogs with experimental MR. This noninvasive technique is suggested to have clinical applications in canine patients with spontaneous MR. Further investigations are required to clarify the clinical significance of this new method in canine heart disease.

## References

- Bargiggia GS, Bertucci C, Recusani F et al. A new method for estimating left ventricular dP/dt by continuous wave Doppler-echocardiography. Validation studies at cardiac catheterization. *Circulation* 1989;80:1287-1292.
- Morita H, Hirabayashi K, Nozaki S et al. Chronic effect of oral mexiletine administration on left ventricular contractility in patients with congestive heart failure: a study based on mitral regurgitant flow velocity measured by continuous-wave Doppler echocardiography. *J Clin Pharmacol* 1995;35:478-483.
- Pai RG, Bansal RC, Shah PM. Doppler-derived rate of left ventricular pressure rise. Its correlation with the postoperative left ventricular function in mitral regurgitation. *Circulation* 1990;82:514-520.
- Broka SM, Ducart AR, Jamart J et al. Doppler-derived left ventricular rate of pressure rise and inotropic requirements during mitral valve surgery. *J Cardiothorac Vasc Anesth* 1998;12:27-32.
- Asano K, Masuda K, Okumura M et al. Plasma atrial and brain natriuretic peptide levels in dogs with congestive heart failure. *J Vet Med Sci* 1999;61:523-529.
- Sellers RD, Levey MJ, Amplatz K, Lillehei CW. Left retrograde cardiography in acquired cardiac disease. *Am J Cardiol* 1964;14:437-447.
- Kienle RD. Cardiac catheterization. In: Kittleson MD, Kienle RD, editors. *Small animal cardiovascular medicine*. Mosby, St. Louis, 1998:118-132.
- Kienle RD, Thomas WP. Echocardiography. In: Nyland TG, Mattoon JS, editors. *Veterinary diagnostic ultrasound*. WB Saunders, Philadelphia, 1995:198-255.
- Ge Z, Zhang Y, Kang W et al. A simultaneous study of Doppler-echo and catheterization in noninvasive assessment of the left ventricular dp/dt. *Clin Cardiol* 1993;16:422-428.
- Chen C, Rodriguez L, Guerrero JL et al. Noninvasive estimation of the instantaneous first derivative of left ventricular pressure using continuous-wave Doppler echocardiography. *Circulation* 1991;83:2101-2110.
- Chen C, Rodriguez L, Lethor JP et al. Continuous wave Doppler echocardiography for noninvasive assessment of left ventricular dP/dt and relaxation time constant from mitral regurgitant spectra in patients. *J Am Coll Cardiol* 1994;23:970-976.
- Kittleson MD, Eyster GE, Knowlen GG et al. Myocardial function in small dogs with chronic mitral regurgitation and severe congestive heart failure. *J Am Vet Med Assoc* 1984;184:455-459.
- Knight DH. Pathophysiology of heart failure and clinical evaluation of cardiac function. In: Ettinger SJ, Feldman EC, editors. *Textbook of veterinary internal medicine*. 4th edn. WB Saunders, Philadelphia, 1995:844-866.
- Kittleson MD. Primary myocardial disease leading to chronic myocardial failure (dilated cardiomyopathy and related diseases). In: Kittleson MD, Kienle RD, editors. *Small animal cardiovascular medicine*. Mosby, St. Louis, 1998:319-346.

(Accepted for publication 27 June 2001)

## Dicoumarol toxicity in cattle associated with ingestion of silage containing sweet vernal grass (*Anthoxanthum odoratum*)

DJ RUNCIMAN<sup>a</sup>, AM LEE<sup>b</sup>, KFM REED<sup>c</sup> and JR WALSH<sup>c</sup>

A diagnosis of dicoumarol toxicity in a herd of Friesian cattle was made following investigation of the deaths of three mature cows and eleven yearling heifers. Affected stock had been fed wrapped, baled silage containing approximately 90% sweet vernal grass (*Anthoxanthum odoratum*). Sweet vernal grass contains coumarin, which can be converted to dicoumarol, a vitamin K antagonist, through the action of moulds. Most deaths were preceded by lethargy, severe

anaemia and subcutaneous and internal haemorrhage. Dicoumarol toxicosis was suspected based on clinical signs, necropsy findings and prolonged prothrombin and activated partial thromboplastin times. Dicoumarol analysis of blood from affected animals and silage confirmed the diagnosis.

*Aust Vet J* 2002;80:28-32

APTT	Activated partial thromboplastin time
Hb	Haemoglobin
PCV	Packed cell volume
PT	Prothrombin time
RCC	Red cell count

<sup>a</sup>Maffra Veterinary Centre, 10 Johnson Street, Maffra, Victoria 3860

<sup>b</sup>Department of Natural Resources and Environment, 78 Henna Street, Warrnambool, Victoria 3280

<sup>c</sup>Agriculture Victoria, Pastoral and Veterinary Institute, Hamilton, Victoria 3300

**D**icoumarol toxicity is a very rare disease in cattle in Australia. It has been reported in cattle fed hay or silage made from sweet vernal grass (*Anthoxanthum odoratum*) in England and the USA.<sup>1-3</sup> The only reported case of dicoumarol toxicity in Australia involved cattle and sheep fed hay with a high content of sweet clover.<sup>4</sup> The current report describes an outbreak of dicoumarol toxicity in a dairy herd in South West Victoria, which had been fed silage with a high content of sweet vernal grass. In a herd of 230 Holstein Friesian dairy cows, seven were affected, of which three died. On the same property, within a group of 70 yearling heifers, eleven died of twenty suspected to have suffered dicoumarol toxicosis.

## Case report

### Clinical signs

An investigation commenced following the deaths of nine yearling heifers and three mature cows. Clinical signs included large subcutaneous and joint swellings in carpal, shoulder and tarsal joints, and haemolactia in one milking cow. Death usually followed a period of illness lasting 3 to 5 days, however three deaths (one cow and two heifers) occurred suddenly in apparently normal stock. Due to poor vaccination history, the stock were initially presumed to be dying from black leg (*Clostridium chauvoei*). However, vaccination did not prevent further deaths and treatment with intramuscular injections of procaine penicillin resulted in large injection site swellings.

The heifers' diet consisted almost entirely of silage cut from a recently purchased out-paddock. The silage had been made into individually wrapped round bales and was approximately 5 months old. Silage represented nearly 100% of their dry matter intake. The bales were fed out in steel 'hay rings'. The milking cows were fed silage as part of their diet, which also included a limited amount of perennial ryegrass pasture, rape and pelleted concentrates. The silage represented approximately 50% of the cow's dry matter intake. The silage was rolled out onto the ground.

Signs of disease first occurred approximately 21 days after silage feeding commenced in both heifers and cows, and continued to occur over a 5 week period. There were no new cases after the feeding of silage ceased.

Over a 3 day period, six heifers were examined, two of which were necropsied. They were aged between 10 and 12 months and weighed about 200 to 250 kilograms.

Initially a live heifer (Heifer 1) was examined. She was standing but reluctant to walk, her left hind leg was grossly swollen and felt hard to touch. Mucous membranes were very pale, rectal temperature was 36.1°C, heart rate 144 beats per minute, and respiratory rate and lung sounds were normal (20 breaths per minute). Rectal examination revealed crepitus in the pelvis and abdomen caudal to the left kidney, which made palpation of her uterus and bladder impossible. A second heifer (Heifer 2), which had died suddenly overnight was necropsied.

Two other heifers, Heifer 3 and Heifer 4, presented the following day with swollen carpal joints. These heifers were both otherwise clinically normal. Arthrocentesis using an 18G, 1.5 inch hypodermic needle was negative for blood. The following day, a heifer (Heifer 5) died suddenly with a bloated abdomen and another heifer developed bilateral carpal swelling (Heifer 6). Approximately twelve other suspected cases that had occurred previously were reported by the stock manager as having shoulder, carpal and tarsal swellings. Of these, seven died between 2 and 5 days after showing signs of swellings.

Incidence and case fatality rates are presented in Table 1, and epidemic histories are represented in Figures 1 and 2.

### Necropsy and histological findings

At necropsy, Heifer 2 had a small subcutaneous haemorrhage over the right flank, small ecchymotic haemorrhages over the serosal surface of the rumen and a large haematoma in the retroperitoneal space surrounding the left kidney, and extending caudally into the pelvis. This haematoma was estimated to be at least 5 L in volume. Histological examination of tissues from this heifer revealed marked haemorrhage into pericapsular adipose tissue of the kidney, but normal renal tissue. There was subendocardial haemorrhage, but the heart was otherwise

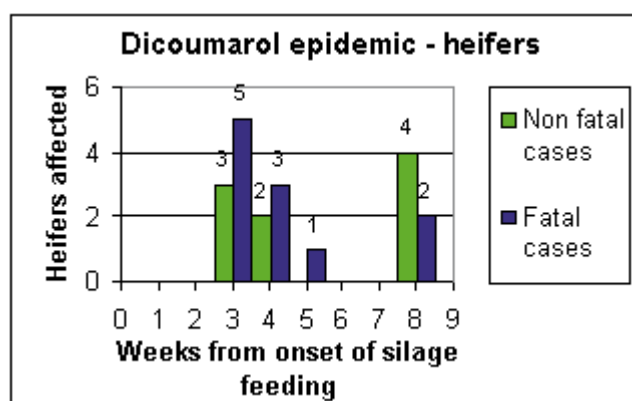
**Table 1. Incidence and case fatality rate for heifers and cows in herd with dicoumarol toxicity.**

Class of stock	Number in group	Morbidity rate <sup>a,c</sup>	Case fatality rate <sup>b,c</sup>
Cows	230	7/230 (3%)	3/7 (42%)
Heifers	70	20/70 (29%)	11/20 (55%)

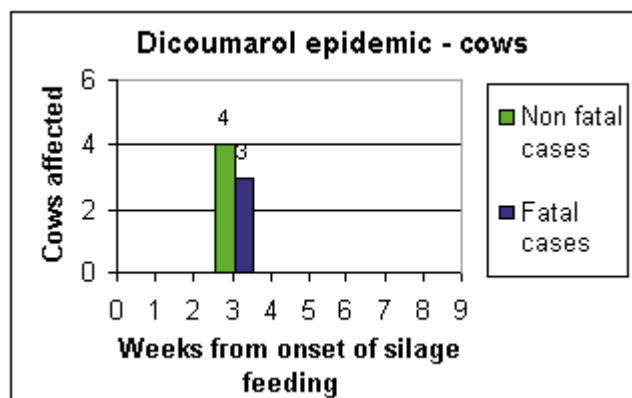
<sup>a</sup>Proportion of group affected over five weeks.

<sup>b</sup>Proportion of cases that died within seven days of onset of clinical signs.

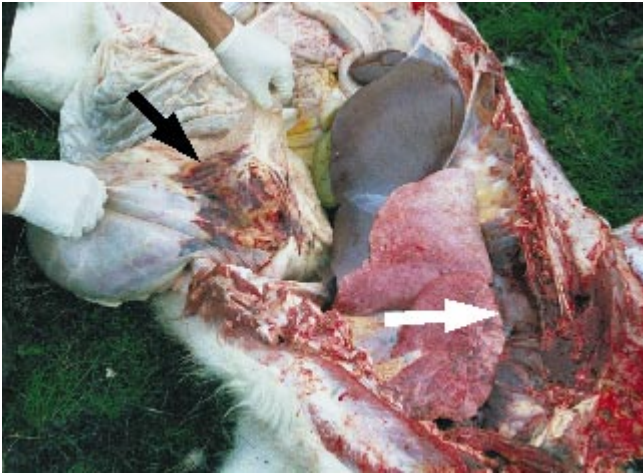
<sup>c</sup>Only the six cases described were confirmed to be dicoumarol toxicosis, other cases were reported by the stock manager or initially diagnosed as other disease.



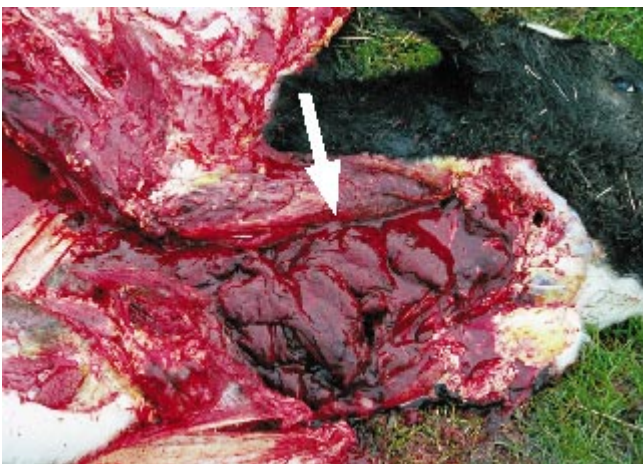
**Figure 1. Dicoumarol epidemic in a herd of 70 Friesian heifers. Cases started to occur three weeks after the onset of feeding silage containing sweet vernal grass. The four non-fatal cases eight weeks after the onset of silage feeding were all treated with vitamin K1.**



**Figure 2. Dicoumarol epidemic in a herd of 230 Friesian cows. As with the heifers in Figure 1, cases started three weeks after the onset of silage feeding.**



**Figure 3.** Necropsy examination of Friesian heifer with dicoumarol toxicity (Heifer 5), revealing haemorrhage on the serosal surface of the omasum (black arrow), and a haematoma within the mediastinum (white arrow).



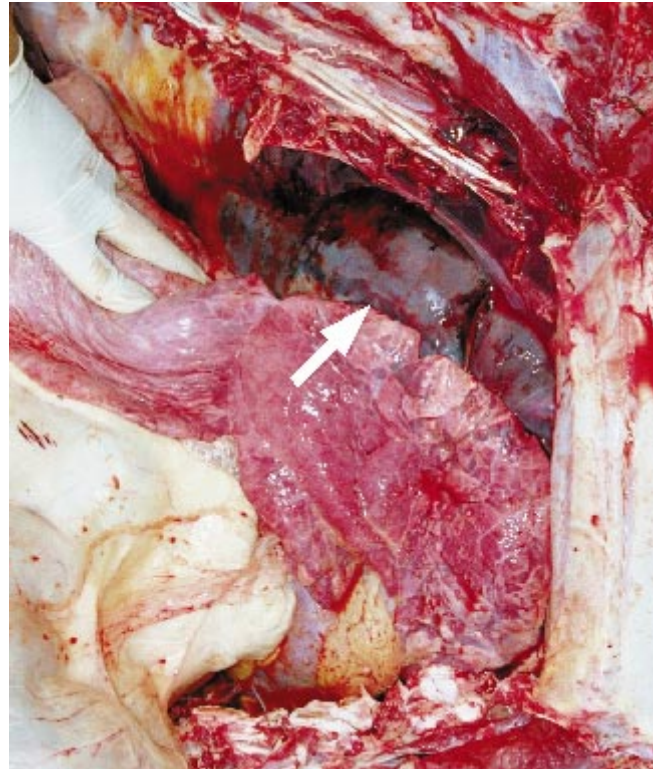
**Figure 5.** Necropsy examination of Friesian heifer with dicoumarol toxicity (Heifer 5). The mediastinal haematoma in Figure 4 extended into the neck and was dissected from around the oesophagus and trachea to the level of the larynx (arrow).

normal. Early degeneration of periacinar hepatocytes was suggestive of hypoxic liver damage. Other tissue samples had unremarkable findings.

Necropsy examination of Heifer 5 revealed a large haemorrhage on the serosal surface of the omasum. There was also a large haematoma in the mediastinum, extending from the diaphragm cranially through the thoracic inlet along the oesophagus and trachea to the level of the larynx. The rumen was distended with gas. It was assumed the haematoma caused pressure on the oesophagus, preventing eructation of gas from the rumen (Figures 3 to 5). There was no histological examination of tissues from Heifer 5.

#### *Results of haematologic examination*

Examination of blood from Heifer 1 revealed profound anaemia and hypoproteinaemia, with normal platelet numbers. Serum biochemical analysis showed no evidence of hepatopathy



**Figure 4.** Haematoma within the mediastinum (arrow) of Friesian heifer with dicoumarol toxicity (Heifer 5). Dissection of this haematoma revealed that it extended from the diaphragm cranially through the thoracic inlet along the oesophagus and trachea to the level of the larynx.

(GLDH, GGT, bilirubin within normal limits) but low serum protein (Table 2). Laboratory findings were consistent with blood loss. Since there was no evidence of external bleeding, it was assumed the crepitus felt in the abdomen and the swollen leg were due to haematomas. Examination of blood from Heifers 3 and 4 was consistent with a coagulation factor deficiency (Table 2).

A coagulopathy was suspected. Bracken fern toxicity was excluded, since there was no possible exposure to bracken fern and platelet numbers were adequate. There was no history of exposure to rodenticides. Based on biochemical analysis of blood from Heifer 1 and histological examination of tissue from Heifer 2, hepatopathy was considered unlikely. Dicoumarol toxicity was suspected, due to feeding silage containing sweet vernal grass.

The remaining three live heifers, Heifers 3, 4 and 6 were treated with 200 mg (approximately 1 mg/kg) vitamin K1 (Koagulon®, phytomenadione 10 mg/mL, Parnell Laboratories, New South Wales) given by subcutaneous injection once daily for 3 days. These heifers recovered. The feeding of affected silage had been discontinued on the first day of this investigation and no further cattle presented with signs of toxicity

#### *Dicoumarol levels*

Lithium heparin and plain blood from Heifers 1 and 4 were sent to the Pastoral and Veterinary Institute in Hamilton, Victoria for dicoumarol analysis. Serum and plasma analysis was based on the method of Van den Berg et al.<sup>5</sup> Dicoumarol was detected in the serum and plasma samples, control samples

Table 2. Haematology results from three heifers with dicoumarol toxicity.

Blood Test (units)	Heifer 1	Heifer 3	Heifer 4	Reference range
PCV (%)	0.09	0.26	0.26	0.24 to 0.46
RBC ( $10^{12}/\text{mL}$ )	2.52	6.61	6.44	5.0 to 10.0
Hb (g/L)	30	95	93	80 to 150
Platelets	326	Adequate	519	100 to 800
Plasma protein (g/L)	53	64	62	60 to 85
Serum protein (g/L)	46	-	-	58 to 80
PT (seconds)	-	96.4	71.8	11 to 17
APTT (seconds)	-	> 120	> 120	31 to 50

were negative. The analysis was essentially a qualitative one because dicoumarol is mostly bound to blood proteins making quantitative measurement difficult.<sup>5</sup>

Laboratory analysis of the silage determined the dry matter content to be 29%. Examination of the bales revealed approximately 90% sweet vernal grass. Most bales were mouldy on the outer layers. Samples of sweet vernal grass from the paddock cut for silage have been catalogued at the National Herbarium of Victoria with reference number 2068475.

A number of representative silage samples were analysed according to the method of Muir et al.<sup>6</sup> Core samples that represented the bale contained dicoumarol at less than one part per million (mg/kg). However, in grab samples representing the outer layer of silage, dicoumarol was detected at the rate of 21 ppm in one sample and 51 ppm in another. We can conclude from these concentrations that the source of the toxin was the outer layers of the silage bales.

## Discussion

Sweet vernal grass is a common grass species in unimproved pasture in south west Victoria. Indigenous to Europe, Asia and North Africa, sweet vernal grass was introduced into Victoria sometime prior to 1887. It is most common in moderate to high rainfall districts and will grow on a wide range of soil types. It becomes obvious in pasture in spring and adapts well to soils of low fertility. In a random survey of 293 pastures carried out in south west Victoria in spring 1989, 47 (16%) contained sweet vernal grass. The content of sweet vernal grass ranged up to 36% (dry matter basis). For the 47 pastures the mean content of sweet vernal was 11% (Quigley PJ, personal communication). While sweet vernal grass is not a rare pasture species in south west Victoria, pastures that are predominantly sweet vernal grass are rare. It is also uncommon to cut silage off an unimproved paddock. These factors could account for the rarity of the disease.

Sweet vernal grass, sweet clover (*Melilotis alba*) and many *Umbelliferae* (for example giant fennel, *Ferula communis*), are examples of herbage species that contain coumarin. Coumarin can be converted to dicoumarol by dimerisation and oxidation through the action of fungal mould species including *Aspergillus*, *Penicillium* and *Mucor*. Conversion to the toxic metabolite occurs when conditions at hay curing or ensilage, for example excess moisture or aerobic conditions, favour fungal growth.<sup>2,3,8,9</sup>

Dicoumarol interferes with synthesis of vitamin K dependent coagulation factors: II (prothrombin), VII (proconvertin), IX (Christmas factor) and X (Stuart factor). These clotting factors are involved in coagulation pathways converting prothrombin

to thrombin, which in turn causes the polymerisation of fibrinogen molecules to fibrin. Impaired fibrin production results in inadequate stabilisation of platelet plugs, making affected animals subject to both internal and external haemorrhages.<sup>10</sup> Clotting factors already present in the blood stream are not affected by dicoumarol and can participate in the clotting cascade, leading to a delay between ingestion of dicoumarol and signs of disease.<sup>7,11</sup>

Reported signs of dicoumarol toxicity include subcutaneous swelling, joint swelling, vaginal bleeding, epistaxis, bloody faeces, pale mucous membranes, colic, tachycardia, tachypnoea, abortions, increased umbilical bleeding in calves and death.<sup>2,7</sup> Clinicians should be aware that bloat may be another clinical presentation of dicoumarol toxicosis. Both PT and APTT are increased in animals with dicoumarol toxicity.<sup>2</sup>

Dicoumarol can be detected in serum, plasma and liver of affected animals.<sup>10</sup> The feed source should also be tested. In this case, different bales and different areas in the bales had different levels of dicoumarol. While Puschner et al state that levels of dicoumarol less than 20 mg/kg are safe to feed to stock, Radostits et al believe that feeds with more than 10 mg/kg should be viewed with caution.<sup>7,10</sup> Feed containing concentrations between 20 mg/kg and 50 mg/kg cause toxic signs if fed consistently for 130 days, and feed containing over 50 mg/kg will cause severe signs when fed for short periods.<sup>7</sup> In the current outbreak one sample was measured at 51 mg/kg. Although the silage had a normal dry matter content and the plastic wrapping on the bales did not appear to be damaged, the bales were considerably spoiled with mould on the outer layers. Higher concentrations of dicoumarol were obtained from silage on the spoiled outer layers. We recommend that several representative samples be taken, especially the outer layers that are more likely to be affected by moulds.

It was noted that affected yearlings were generally the older and larger ones. One could infer that these stock competed for first access to the bales, eating more of the outer layer of silage spoiled by fungi and with a higher dicoumarol content. When fed to the milking cows, bales were rolled out on the ground. It is likely that only the first layer or two contained toxic levels of dicoumarol. This, coupled with the reduced overall intake of silage compared to the heifers, would account for a lower prevalence of disease in the cows compared to the heifers.

The left over silage was fed to the milking cows, however the outer layers were discarded and the silage was fed for 3 days at a time, then not fed for a week. It was also fed as a minor component of their diet (approx 10% of total dry matter intake) to minimise exposure to high levels of dicoumarol. No further cases of toxicosis developed.

Treatment can include blood transfusions, which are generally indicated if PCV falls below 12%.<sup>2,12</sup> Animals should be taken off affected feed immediately and stock showing signs should receive vitamin K1. Doses of 1.1, 2.2 and 3.3 mg/kg of vitamin K1 have all been used to treat dicoumarol toxicity.<sup>13</sup> Current recommendations are that vitamin K1 be administered at a dosage of 1 to 3 mg/kg every 12 hours for 5 days or until PT and APTT return to normal ranges. The animals in this report were treated once daily for 3 days and had not been exposed to feed for 5 days by the time treatment commenced. The injections were given subcutaneously to minimise injection haematomas. It is recommended that a fine gauge needle and different injection sites be used. Vitamin K3 is not an effective treatment for dicoumarol toxicity.<sup>11,13</sup>

Veterinarians, advisors and farmers should be aware that silage in which sweet vernal grass is dominant can lead to dicoumarol toxicity and that an outbreak of this toxicity has occurred in Australia.

### Acknowledgment

The authors appreciate the editorial assistance of Dr John Morton, Warrnambool.

### References

1. Cranwell MP. Acute fatal haemorrhagic syndrome in dairy cows. *Vet Rec* 1983;112:486.
2. Bartol JM, Thompson LJ, Minnier SM, Divers TJ. Hemorrhagic diathesis, mesenteric hematoma, and colic associated with ingestion of sweet vernal grass in a cow. *J Am Vet Med Assoc* 2000;216:1605-1608.
3. Pritchard DG, Markson LM, Brush PJ, Sawtell JAA, Bloxham PA. Haemorrhagic syndrome of cattle associated with the feeding of sweet vernal (*Anthoxanthum odoratum*) hay containing dicoumarol. *Vet Rec* 1983;113:78-84.
4. Wignall WN, Banks AW, Hackett MA, Irving A. Dicoumarol poisoning of cattle

- and sheep in South Australia. *Aust Vet J* 1961;37:456-459.
5. Van den Berg JHM, Wielders JPM, Scheerer PJH. Determination of anticoagulants in serum by column liquid chromatography. *J Chrom* 1977;144:266-269.
6. Muir AD, Goplen BP. Quantitative reverse phase HPLC analysis of dicoumarol in sweet clover (*Mellilotus alba*) hay and silage samples. *J Agric Food Chem* 1992;40:820-823.
7. Puschner B, Galey FD, Holstege DM, Palazoglu M. Sweet clover poisoning in dairy cattle in California. *J Am Vet Med Assoc* 1998;212:857-859.
8. Tligui N, Ruth GR. *Ferula communis* variety *brevifolia* intoxication of sheep. *Am J Vet Res* 1994;55:1558-1563.
9. Landau SY, Ben-Moshe E, Egber A et al. Conditioned aversion to minimize *Ferula communis* intake by orphan lambs. *J Range Manag* 1999;52:429-432.
10. Radostits OM, Gay CC, Blood DC, Hinchcliff KW. *Veterinary Medicine*. 9th edn. WB Saunders, London, 2000:1645-1647.
11. Radostits OM, Searcy GP, Mitchell KG. Mouldy sweet clover poisoning in cattle. *Can Vet J* 1980;21:155-158.
12. Radostits OM, Gay CC, Blood DC, Hinchcliff KW. *Veterinary Medicine*. 9th edn. Saunders, London, 2000:405.
13. Alstad AD, Casper HH, Johnson LJ. Vitamin K treatment of sweet clover poisoning in calves. *J Am Vet Med Assoc* 1985;187:729-731.

(Accepted for publication 11 July 2001)

## Unusual ovarian activity in a mare preceding the development of an ovarian granulosa cell tumour

CHOPIN JB<sup>a</sup>, CHOPIN LK<sup>b</sup>, KNOTT LM<sup>c</sup>, DE KRETSEK DM<sup>d</sup> and DOWSETT KF<sup>e</sup>

An 8-year-old mare, with a foal at foot, was inseminated on foal heat with frozen semen, with the resultant pregnancy lost between days 34 and 41. The right ovary developed a large anovulatory follicle that was non-responsive to multiple doses of ovulating agents. The follicle eventually appeared to luteinise, although plasma progesterone concentrations did not reflect this. Another follicle developed, responded to GnRH and resulted in a pregnancy from frozen semen that went to term with a healthy foal. When the mare was examined after foaling, the structure on the right ovary appeared to be a granulosa cell tumour; the left ovary was smaller than normal and non-functional. Surgical removal of the right ovary before increasing photoperiod resulted in a return to function of the left ovary and a pregnancy to frozen semen on the second cycle following removal. Figures showing concentrations of inhibin, progesterone, androstenedione, oestradiol and testosterone are presented for this entire period. Unusual ovarian activity in the mare might be a prelude to the development of a granulosa cell tumour.

*Aust Vet J* 2002;80:32-36

<sup>a</sup>Oakey Veterinary Hospital, PO Box 2, Oakey, Queensland 4401

<sup>b</sup>Center for Molecular Biotechnology, School of Life Sciences, QUT, GPO Box 2434, Queensland 4001

<sup>c</sup>Animal Health and Production, University of Queensland, PO Box 125, Kenmore, Queensland 4069

<sup>d</sup>Institute of Reproduction & Development, 246 Clayton Road, Clayton, Victoria 3168

<sup>e</sup>43 Southerden Avenue, The Grange, Queensland 4051

Although rare, benign granulosa cell tumours are one of the most common neoplasms of mares<sup>1</sup> and may occur at any age.<sup>1-3</sup> The diagnosis of most granulosa cell tumours is made after examination of a mare exhibiting unusual behaviour, poor reproductive performance, or an enlarged ovary as an incidental finding on rectal palpation.<sup>1,4</sup> A definitive diagnosis is made by the observation of typical histopathological changes.<sup>5</sup>

Grossly, ovaries affected by granulosa cell tumours are enlarged.<sup>6</sup> The cut surface is yellow to gray, exhibiting prominent cystic structures or microcysts.<sup>7-9</sup> The contralateral ovary is frequently diminished in size.<sup>2,7</sup> Surgical removal is the treatment of choice for granulosa cell tumours, and after surgery many mares return to oestrus, are capable of breeding and behaviour normalises.<sup>1,2,4,9</sup>

The measurement of hormone concentrations may aid in the diagnosis of granulosa cell tumours. Granulosa cell tumours secrete a range of hormones,<sup>10-14</sup> including varying amounts of progesterone, oestrogen, androstenedione and inhibin. In one study, increased plasma inhibin concentrations were observed in 87% of cases and elevated testosterone in 50% of cases.<sup>15</sup> Oestrogen concentrations vary considerably, and if elevated are

eCG	Equine chorionic gonadotrophin
FSH	Follicle stimulating hormone
GnRH	Gonadotrophin releasing hormone
LH	Luteinising hormone